

Three - Dimensional Temporomandibular Joint and Mandibular Morphology in A Group of Thai Skeletal Class III with and Without Mandibular Asymmetry Using Cone Beam Computed Tomography

Yosaphon Songphum¹, Sirima Petdachai¹, Vannaporn Chuenchompoonut²

¹Department of Orthodontics, Faculty of Dentistry, Chulalongkorn University, Bangkok, Thailand

²Department of Radiology, Faculty of Dentistry, Chulalongkorn University, Bangkok, Thailand

Abstract

The aims of this study were to evaluate the temporomandibular joint (TMJ) and mandibular morphology in skeletal Class III patients, compare the dimensions between symmetric and asymmetric patients, and find the correlation of the dimensions. Eighty Cone Beam Computed Tomography images of adult Thai skeletal Class III patients (20 adult males, 20 adult females, aged 20-42 years, mean age 25.45 ± 6.05 years) were divided into eight groups. The TMJ and mandible dimensions and angulations were measured using multiplanar reconstruction images. The differences in the dimensions between groups were analyzed using ANOVA and the Kruskal Wallis H test. The correlations of the dimensions were analyzed by the Pearson correlation and the Spearman correlation. The ICC was good-excellent for the intra-examiner (0.843–0.993) and inter-examiner reliability (0.833–0.980). The TMJ and mandibular measurements were significantly different between groups in the mediolateral condylar width, anteroposterior condylar width, coronal condylar angle, ramus width, ramus height, and mandibular height. However, there were no significant differences between groups for the condylar axis, sagittal condylar angle, superior joint space, anterior joint space, posterior joint space, condylar height, glenoid fossa depth, coronoid height, coronoid width, anterior fossa inclination, posterior fossa inclination, lingula, and gonial angle. The correlation between the lingula position and ramus height ($r = 0.743$), the ramus width and mandibular height ($\rho = 0.798$), and the mandibular height and the ramus height ($\rho = 0.740$) were good. In conclusion, comparing the TMJ and mandible revealed that the male non-deviated side exhibited the greatest mediolateral and anteroposterior condylar width, ramus height, and mandibular height. Skeletal Class III symmetry patients demonstrated a significant correlation between the lingula position and ramus height, the mandibular height and ramus height, and between the mandibular height and ramus width.

Keywords: Asymmetry, Cone-beam computed tomography, Skeletal Class III, Temporomandibular joint

Received date: Sep 11, 2024

Revised date: Oct 19, 2024

Accepted date: Oct 26, 2024

Doi:

Correspondence to:

Yosaphon Songphum, Department of Orthodontics, Faculty of Dentistry, Chulalongkorn University, Henri Dunant Road, Wangmai, Patumwan, Bangkok, Thailand 10330. Tel: 02-218-8951 Email: poe_yosaphon@hotmail.com

Introduction

The practice of orthodontics is not limited to treating tooth misalignments. The clinician is often

confronted with patients that require treatment of craniofacial abnormalities that impact their appearance.

The temporomandibular joint (TMJ) and mandible are a part of the facial skeleton that can impact the appearance of a patient. Previous studies reported that the TMJ was different based on various factors comprising age, sex, skeletal relationships, and ethnicity.^{1,2} The TMJ size changes during the growth period, especially the mediolateral dimension of the condyle.^{3,4} The growth-induced increase in the TMJ size is decreased when the patient becomes an adult. However, the bone remodeling process that occurs throughout life affects the TMJ and mandibular shape.⁵ The anteroposterior skeletal relationship is classified into skeletal Class I, II, and III that refer to a normal maxillomandibular relationship, the maxilla is more anterior than the mandible, and the mandible is more anterior than the maxilla, respectively. Compared with the Class I and Class II skeletal patterns, skeletal Class III had a higher anteroposterior condylar inclination and lower superior joint space.² The TMJ and mandible in males and females differ in size between the sexes, e.g., the coronoid height in Brazilian males was higher than in females.⁶ The TMJ size is also influenced by ethnicity, and the Asian population has differences in TMJ morphology. A Southeast Asian population study revealed that the condylar height in Chinese individuals was significantly higher than in Malays.¹ The TMJ and mandibular morphology is important for clinical orthodontic practice to generate the orthognathic surgical treatment plan and evaluate treatment outcome.

One of the problems in an orthodontic patient is skeletal asymmetry. A report in Koreans comparing Class III symmetric and asymmetric patients demonstrated that the superior joint space on the deviated side is narrower than the non-deviated side and the joint space of symmetric patients.⁷ Patients with a symmetric facial skeleton and severe skeletal Class III were usually treated with orthognathic surgery. The combination of skeletal Class III malocclusion and skeletal asymmetry requires more complex treatment procedures.⁸ The surgical treatment in asymmetric Class III patients corrects the skeleton in the anteroposterior and transverse directions by surgery.⁹ Understanding the structures that affect skeletal asymmetry is important for surgical correction in adult patients or attempting to correct the skeleton morphology by growth modification in growing patients.

A TMJ morphological study can be performed using different methods, i.e., a dry skull, conventional two-dimensional images, or three-dimensional images. However, cone beam computed tomography (CBCT) provides better precision for investigating the TMJ area than a panoramic radiograph.¹⁰ The multiplanar reconstruction images of a CBCT have a lower radiation dose than conventional computed tomography.¹¹ Moreover, the TMJ measurements using CBCT images are highly accurate compared with those of the actual TMJ.¹² To the best of our knowledge, the TMJ and mandibular morphology in Thai skeletal Class III asymmetric patients investigated using CBCT has not been reported. Thus, the purpose of this study was to compare the TMJ and mandibular dimensions between groups of Thai symmetric skeletal Class III patients and asymmetric skeletal Class III patients using CBCT. This information can provide reference data for diagnosis and treatment planning in skeletal Class III patients with and without asymmetry.

Materials and methods

This study was a retrospective study that measured the TMJ and mandibular dimensions using CBCT images of skeletal Class III Thai patients. The research protocol was approved by the Ethics Committee of the Faculty of Dentistry, Chulalongkorn University (HREC-DCU 2020-114). The sample size was forty patients (eighty CBCT images) calculated by the difference between two independent mean formulas using 0.05 alpha level, 0.2 beta level together with the means and standard deviations of the condylar length from the study of Alhammadi *et al.*² Eighty CBCT images of the TMJs from 40 patients were taken at the Department of Radiology with a standard protocol between January 2013–October 2021 by two CBCT machines, i.e., 3D Accuitomo 170 (J. Morita, Kyoto, Japan) with 90 kVp, 5–10 mA, 17.5 sec scanning time, 17x12 mm field of view (FOV), and 0.25 mm voxel size and i-CAT (Imaging Sciences International, Hatfield, PA, USA) with 120 kVp, 3–8 mA, 7.4 sec scanning time, 23x17 mm FOV, and 0.25 mm voxel size. The CBCT images of the left and right TMJs were randomly selected and analyzed with a purposive requirement. The inclusion criteria comprised 1) Thai patients, 2) Age \geq 20 years, 3) Skeletal Class III categorized by Wits appraisal (value less than

-5 mm), 4) No history of trauma, 5) No history of TMJ or mandible surgery, 6) No TMJ and mandible pathology based on the CBCT images and medical record, 7) No congenital abnormality of the TMJ and mandible. The exclusion criteria comprised 1) Pseudo Class III malocclusion, 2) Low-quality CBCT image, 3) Medical history of systemic diseases that affect the development of the TMJ and mandible. The symmetric group was classified by a Menton deviation ≤ 3 mm from the midsagittal plane and the asymmetric group had a Menton deviation > 3 mm from the midsagittal plane. Based on these criteria, 80 CBCT images of 20 symmetry patients (nine males, 11 females), and 20 asymmetric patients (eight males, 12 females), aged 20–42 years, mean age 25.45 ± 6.05 years, were obtained. The TMJ and mandibular images were classified into eight subgroups: 1) male left side, 2) male right side, 3) male deviated side, 4) male non-deviated

side, 5) female left side, 6) female right side, 7) female deviated side and 8) female non-deviated side. The CBCT images were oriented and measured using Infinitt® PACS software (Version 1.0 Infinitt Healthcare Co., Ltd., Seoul, Korea). The linear and angular measurements were performed using multiplanar reconstruction images when each plane was perpendicular to the other planes. The TMJ and mandibular dimensions were separately measured on the left and right sides. In the axial slice, the distance of the structures was measured after the maximum width was determined in the sagittal and coronal slices. The sagittal slice measurements were made after adjusting the Frankfort horizontal plane parallel to the floor. The CBCT landmarks and measurements are demonstrated in Figure 1A to 1E and Table 1, respectively. All measurements were performed by a single examiner. The examiner performed a single measure for each measurement.

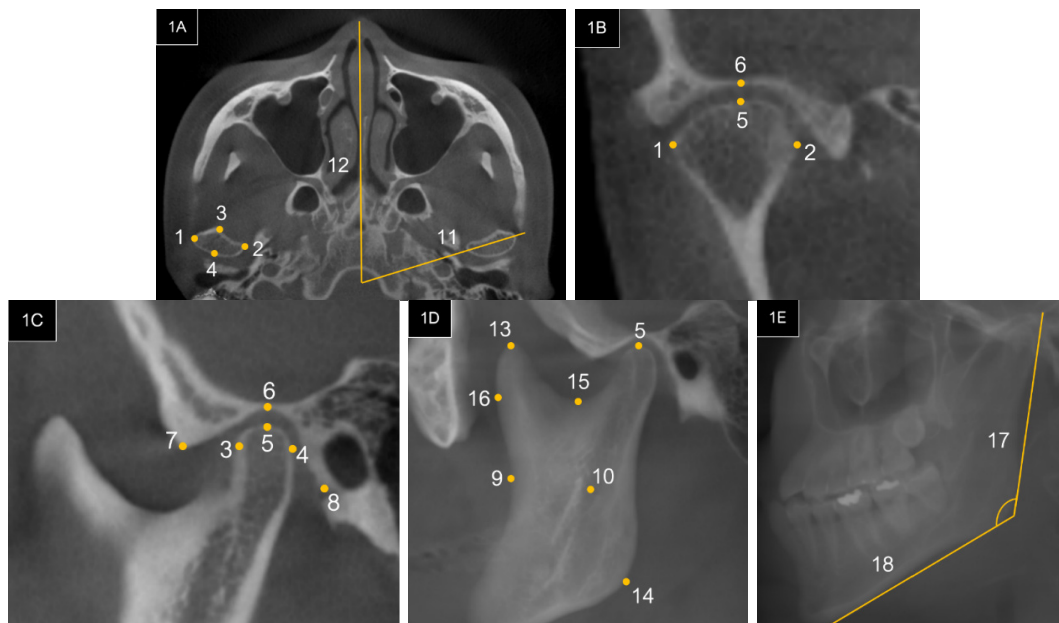


Figure 1A 1) Point No.1 Most lateral point of the condyle 2) Point No.2 Most medial point of the condyle
3) Point No.3 Most anterior point of the condyle 4) Point No.4 Most posterior point of the condyle
5) Line No.11 The line connecting the medial and lateral point of the condyle 6) Line No.12 Midsagittal plane

Figure 1B 1) Point No.1 Most lateral point of the condyle 2) Point No.2 Most medial point of the condyle
3) Point No.5 Most superior point of the condyle 4) Point No.6 Deepest point of the Glenoid fossa

Figure 1C 1) Point No.3 Most anterior point of the condyle 2) Point No.4 Most posterior point of the condyle
3) Point No.5 Most superior point of the condyle 4) Point No.6 the deepest point of the Glenoid fossa
5) Point No.7 Articular eminence 6) Point No.8 Postglenoid tubercle

Figure 1D 1) Point No.9 Coronoid notch 2) Point No.10 Lingula 3) Point No.13 Most superior of the Coronoid process
4) Point No.14 Gonion 5) Point No.15 Deepest point of the Sigmoid notch 6) Point No.16 Anterior surface of the Coronoid notch at the deepest point of the Sigmoid notch level

Figure 1E 1) Line No.17 Posterior ramus plane 2) Line No.18 Mandibular plane

Statistical analysis

Intraclass correlation coefficient (ICC) was used to analyze the intra-examiner and inter-examiner reliabilities. To evaluate the intra-examiner reliability, ten randomly selected samples were re-measured by the investigator within two weeks and analyzed using ICC. The inter-examiner reliability was evaluated by ICC that compared the measurements from the ten randomly selected samples between the investigator and the experienced radiologist. The normality test of the measurements was analyzed by the Shapiro-Wilk test. The difference in linear and angular measurements was analyzed by

one-way ANOVA. Post hoc analysis was performed by the LSD test. The Kruskal Wallis H test was used to compare the linear and angular measurements between groups when the Shapiro-Wilk test showed that the variable was not normally distributed. The correlation among the linear and angular measurements was analyzed using Pearson's correlation. Spearman correlation was used to analyze the measurements when the variable was not normally distributed. The statistical analyses were performed using the Statistical Package for the Social Sciences (SPSS 22.0; SPSS Inc., Chicago, IL, USA). Significance was defined at $p < 0.05$.

Table 1 Measurement definitions

Measurements (Abbreviation)	Definition
Mediolateral condylar width (ML)	No.1 to No.2 distance
Anteroposterior condylar width (AP)	No.3 to No.4 distance
Condylar height (CoH)	No.5 perpendiculars to the line paralleled Frankfort horizontal plane and passed through No.15 distance
Condylar axis (CoA)	Angle intersected between No.11 and No.12
Coronal condylar angle (Cor)	Angle intersected between the line passed through No.1 to No.5 and the line passed through No.2 to No.5
Sagittal condylar angle (Sag)	Angle intersected between the line passed through No.4 to No.5 and the line passed through No.4 to No.5
Superior joint space (SS)	No. 5 perpendiculars to fossa distance
Anterior joint space (AS)	No. 3 perpendiculars to fossa distance
Posterior joint space (PS)	No. 4 perpendiculars to fossa distance
Anterior fossa inclination (AFI)	Angle intersected between the line passed through No.6 to No.7 and the line passed through No.7 to No.8
Posterior fossa inclination (PFI)	Angle intersected between the line passed through No.6 to No.8 and the line connecting No.7 to No.8
Glenoid fossa depth (FD)	No.6 perpendiculars to the line passed through No.7 and No.8 distance
Coronoid width (CW)	No.15 to No.16 distance
Coronoid height (CH)	No.13 perpendiculars to the line passed through No.15 and No.16
Ramus width (RW)	No.9 to posterior ramus border distance
Ramus height (RH)	No.14 perpendiculars to the line paralleled Frankfort horizontal plane and passed through No.15 distance
Mandibular height (MH)	No.14 to No.5 distance
Gonial angle (GO)	Angle intersected between No.17 and N.18
Lingula position (Li)	No.10 perpendiculars to the line paralleled Frankfort horizontal plane and passed through No.15 distance

Results

The ICC results were good-excellent for the intra-examiner reliability (0.843–0.993) and inter-examiner reliability (0.833–0.980). Comparing the temporomandibular joint

and mandibular measurements demonstrated that the mediolateral condylar width of the male non-deviated side was significantly higher compared with the male left

side ($p = 0.003$), male right side ($p = 0.009$), female left side ($p = 0.006$), female right side ($p = 0.001$), female deviated side ($p = 0.001$), and female non-deviated side ($p = 0.004$). Moreover, the anteroposterior condylar width of the male non-deviated side was significantly higher compared with the male left side ($p = 0.016$), male right side ($p < 0.001$), male deviated side ($p = 0.024$), female left side ($p = 0.002$), female right side ($p = 0.001$), female deviated side ($p < 0.001$), and female non-deviated side ($p = 0.003$). The ramus height of the male non-deviated side was significantly higher compared with the female left side ($p = 0.007$), female right side ($p = 0.003$), female deviated side ($p = 0.029$), and female non-deviated side ($p = 0.027$). The ramus height of the male right side was significantly higher compared with the female left side ($p = 0.013$), female right side ($p = 0.006$), and female non-deviated side ($p = 0.048$). The ramus height of the male deviated side was significantly higher compared with the female left side ($p = 0.025$) and female right side ($p = 0.014$). The ramus width of the male deviated side group was significantly higher compared with the female left side ($p = 0.010$), female right side ($p = 0.011$), female deviated side ($p = 0.012$), and female non-deviated side ($p = 0.008$). The ramus width of the male non-deviated side was significantly higher compared with the female left side ($p = 0.019$), female right side ($p = 0.020$), female deviated side ($p = 0.022$), and female

non-deviated side ($p = 0.015$). The coronal condylar angle of the male deviated side was significantly lower compared with the female left side ($p = 0.039$).

The coronoid width of the female left side and right side was significantly lower compared with the male right side, male deviated side, and male non-deviated side. The mandibular height of the female left side was significantly lower compared with the male left side ($p = 0.028$), male right side ($p = 0.012$), male deviated side ($p = 0.004$), male non-deviated ($p < 0.001$), and female non-deviated side ($p = 0.005$). The mandibular height of the female right side was significantly lower compared with the male left side ($p = 0.045$), male right side ($p = 0.020$), male deviated side ($p = 0.007$), male non-deviated ($p < 0.001$), and female non-deviated side ($p = 0.009$). The mandibular height of the female deviated side was significantly lower compared with the male right side ($p = 0.039$), male deviated side ($p = 0.013$), male non-deviated ($p < 0.001$), and female non-deviated side ($p = 0.019$). There were no significant differences between groups for the condylar axis, sagittal condylar angle, superior joint space, anterior joint space, posterior joint space, condylar height, glenoid fossa depth, coronoid height, coronoid width, anterior fossa inclination, posterior fossa inclination, lingula, and gonial angle (Table 2, 3, and 4).

Table 2 Mean and standard deviation (SD) value of TMJ and mandibular measurements in males

Measurements	Group 1		Group 2		Group 3		Group 4	
	Male left side		Male right side		Male deviated side		Male non-deviated side	
	Mean	SD	Mean	SD	Mean	SD	Mean	SD
ML (mm)	17.16	1.49	17.55	1.57	18.63	2.33	19.86	1.87
AP (mm)	7.87	0.52	7.17	0.95	7.92	1.45	9.19	1.72
CoH (mm)	21.47	3.65	20.10	4.10	21.01	4.13	22.66	3.54
CoA (°)	73.23	10.98	68.65	9.23	71.61	7.05	72.59	8.43
Cor (°)	117.39	7.54	116.30	5.95	112.80	8.33	110.09	9.33
Sag (°)	99.33	10.83	104.60	6.99	109.34	8.75	112.23	9.76
SS (mm)	1.68	0.41	1.68	0.50	2.10	0.49	2.16	0.73
AS (mm)	2.31	0.42	2.26	0.43	2.31	0.56	2.23	0.67
PS (mm)	1.96	0.58	2.00	0.36	1.78	0.77	1.84	0.69
AFI (°)	51.05	5.96	51.91	6.31	52.46	3.96	51.75	4.85

Table 2 Mean and standard deviation (SD) value of TMJ and mandibular measurements in males (cont.)

Measurements	Group 1		Group 2		Group 3		Group 4	
	Male left side		Male right side		Male deviated side		Male non-deviated side	
	Mean	SD	Mean	SD	Mean	SD	Mean	SD
PFI (°)	34.59	3.42	33.28	3.98	36.95	2.81	36.01	3.52
FD (mm)	11.82	1.25	12.01	1.17	11.72	0.67	11.68	0.95
CH (mm)	11.47	2.24	10.81	1.67	13.31	3.29	9.90	2.57
CW (mm)	18.89	2.21	19.30	1.62	20.53	3.22	21.24	3.82
RH (mm)	39.26	6.03	41.63	5.56	41.25	3.34	42.27	3.53
RW (mm)	31.26	4.31	30.69	3.60	33.09	4.46	32.72	3.74
MH (mm)	62.04	7.70	62.85	7.91	64.09	6.34	67.03	4.22
GO (°)	130.69	6.88	129.56	5.07	130.00	4.85	132.76	7.89
Li (mm)	21.60	3.60	22.88	4.08	22.27	2.07	21.93	2.17

SD indicates standard deviation

Table 3 Mean and standard deviation (SD) value of the TMJ and mandibular measurements in females

Measurements	Group 5		Group 6		Group 7		Group 8	
	Female left side		Female right side		Female deviated side		Female non-deviated side	
	Mean	SD	Mean	SD	Mean	SD	Mean	SD
ML (mm)	17.54	1.34	17.12	1.75	17.17	2.00	17.48	1.77
AP (mm)	7.58	0.89	7.46	0.76	7.43	1.16	7.65	1.07
CoH (mm)	18.91	3.93	19.58	4.32	17.57	3.36	21.71	2.71
CoA (°)	69.31	6.52	69.29	7.44	68.67	9.32	72.28	7.36
Cor (°)	125.23	10.23	122.61	16.30	115.41	8.96	114.57	6.58
Sag (°)	106.27	8.87	105.04	8.34	106.44	8.98	110.50	5.03
SS (mm)	1.80	0.68	1.86	0.67	1.88	0.56	1.60	0.36
AS (mm)	2.45	0.62	2.36	0.39	2.09	0.57	1.76	0.36
PS (mm)	2.34	0.60	2.45	0.45	1.82	0.57	1.86	0.55
AFI (°)	50.94	6.88	52.51	7.10	53.51	3.51	51.73	4.16
PFI (°)	37.01	5.08	34.96	3.42	35.70	2.68	35.79	1.75
FD (mm)	10.47	1.19	11.36	1.27	11.16	0.78	11.25	1.10
CH (mm)	10.17	1.77	10.36	2.36	12.33	3.00	11.24	3.84
CW (mm)	16.71	2.58	16.90	1.98	18.26	2.16	17.74	2.03
RH (mm)	36.56	4.51	36.05	4.27	37.77	3.34	37.71	4.17
RW (mm)	29.15	1.98	29.18	2.20	29.30	2.60	29.08	2.74
MH (mm)	56.62	4.33	57.10	3.86	57.87	4.36	63.15	3.73
GO (°)	127.79	5.67	128.07	6.06	128.42	6.46	130.32	5.23
Li (mm)	21.55	3.34	20.98	2.56	20.55	2.50	20.80	2.16

SD indicates standard deviation

Table 4 Comparison of the temporomandibular joint and mandibular measurements

Measurement	Comparison between groups
ML (mm)	1-4 ($p = 0.003$) [‡] , 2-4 ($p = 0.009$) [‡] , 4-5 ($p = 0.006$) [‡] , 4-6 ($p = 0.001$) [‡] , 4-7 ($p = 0.001$) [‡] , 4-8 ($p = 0.004$) [‡]
AP (mm)	1-4 ($p = 0.016$) [‡] , 2-4 ($p < 0.001$) [‡] , 3-4 ($p = 0.024$) [‡] , 4-5 ($p = 0.002$) [‡] , 4-6 ($p = 0.001$) [‡] , 4-7 ($p < 0.001$) [‡] , 4-8 ($p = 0.003$) [‡]
CoH (mm)	NS
CoA (°)	NS
Cor (°)	3-5 ($p = 0.039$) ^{††}
Sag (°)	NS
SS (mm)	NS
AS (mm)	NS
PS (mm)	NS
AFI (°)	NS
PFI (°)	NS
FD (mm)	NS
CH (mm)	NS
CW (mm)	NS
RH (mm)	2-5 ($p = 0.013$) [‡] , 2-6 ($p = 0.006$) [‡] , 2-8 ($p = 0.048$) [‡] , 3-5 ($p = 0.025$) [‡] , 3-6 ($p = 0.014$) [‡] , 4-5 ($p = 0.007$) [‡] , 4-6 ($p = 0.003$) [‡] , 4-7 ($p = 0.029$) [‡] , 4-8 ($p = 0.027$) [‡]
RW (mm)	3-5 ($p = 0.010$) [‡] , 3-6 ($p = 0.011$) [‡] , 3-7 ($p = 0.012$) [‡] , 3-8 ($p = 0.008$) [‡] , 4-5 ($p = 0.019$) [‡] , 4-6 ($p = 0.020$) [‡] , 4-7 ($p = 0.022$) [‡] , 4-8 ($p = 0.015$) [‡]
MH (mm)	1-5 ($p = 0.028$) [‡] , 1-6 ($p = 0.045$) [‡] , 2-5 ($p = 0.012$) [‡] , 2-6 ($p = 0.020$) [‡] , 2-7 ($p = 0.039$) [‡] , 3-5 ($p = 0.004$) [‡] , 3-6 ($p = 0.007$) [‡] , 3-7 ($p = 0.013$) [‡] , 4-5 ($p < 0.001$) [‡] , 4-6 ($p < 0.001$) [‡] , 4-7 ($p < 0.001$) [‡] , 5-8 ($p = 0.005$) [‡] , 6-8 ($p = 0.009$) [‡] , 7-8 ($p = 0.019$) [‡]
GO (°)	NS
Li (mm)	NS

Group 1, male left side; Group 2, male right side; Group 3, male deviated side; Group 4, male non-deviated side;

Group 5, female left side; Group 6, female right side; Group 7, female deviated side; Group 8, female non-deviated side

[‡]Significant difference between groups ($p < 0.05$, ANOVA, LSD test)

^{††}Significant difference between groups ($p < 0.05$, Kruskal Wallis H test)

NS, No significant group differences at .05 level

The correlation of the temporomandibular joint and mandibular measurements in skeletal Class III symmetry revealed that the lingula position was highly correlated with the ramus height ($r = .743$). The mandibular

height of the skeletal Class III symmetry showed a high correlation with the ramus width ($p = 0.798$) and height ($p = 0.740$). (Table 5).

Table 5 Correlation of the TMJ and mandibular measurements of Skeletal Class III symmetry patients

Measurement	RH	MH	Li	SS	AS	PS
ML (mm)	.216 [‡]	.226 [†]	-.186 [‡]	.081 [†]	.211 [†]	.040 [‡]
AP (mm)	.303 [‡]	.279 [†]	.136 [‡]	.175 [†]	-.017 [†]	.269 [‡]
CoH (mm)	-.158 [‡]	.418 [†]	-.453 [‡]	-.521 [†]	.319 [†]	-.075 [‡]
CoA (°)	.026 [‡]	.076 [†]	.372 [‡]	-.054 [†]	.002 [†]	-.089 [‡]
Cor (°)	-.196 [†]	-.475 [†]	-.038 [†]	.377 [†]	-.158 [†]	.291 [†]
Sag (°)	-.243 [†]	-.175 [†]	.555 [†]	-.305 [†]	-.039 [†]	.135 [†]
SS (mm)	.288 [†]	.054 [†]	.139 [†]	1 [†]	.179 [†]	.189 [†]
AS (mm)	.024 [†]	.367 [†]	-.287 [†]	.179 [†]	1 [†]	.210 [†]

Table 5 Correlation of the TMJ and mandibular measurements of Skeletal Class III symmetry patients (cont.)

Measurement	RH	MH	Li	SS	AS	PS
PS (mm)	-.198 [‡]	-.134 [‡]	.320 [‡]	.189 [‡]	.210 [‡]	1 [‡]
AFI (°)	.289 [‡]	.299 [‡]	.249 [‡]	.324 [‡]	.255 [‡]	-.224 [‡]
PFI (°)	.036 [‡]	-.071 [‡]	.602 [‡]	.050 [‡]	-.174 [‡]	-.281 [‡]
FD (mm)	.555 [‡]	.581 [‡]	.337 [‡]	.029 [‡]	.174 [‡]	-.258 [‡]
CH (mm)	.064 [‡]	-.031 [‡]	.558 [‡]	.006 [‡]	-.283 [‡]	-.013 [‡]
CW (mm)	.541 [‡]	.548 [‡]	.158 [‡]	.148 [‡]	.287 [‡]	-.130 [‡]
RH (mm)	1 [‡]	.740 [‡]	.743 [‡]	.288 [‡]	.024 [‡]	-.198 [‡]
RW (mm)	.411 [‡]	.798 [‡]	.639 [‡]	.010 [‡]	.465 [‡]	-.081 [‡]
MH (mm)	.740 [‡]	1 [‡]	.041 [‡]	.054 [‡]	.367 [‡]	-.134 [‡]
GO (°)	-.315 [‡]	-.475 [‡]	-.086 [‡]	-.032 [‡]	-.292 [‡]	-.038 [‡]
Li (mm)	.743 [‡]	.041 [‡]	1 [‡]	.139 [‡]	-.287 [‡]	.320 [‡]

The positive value is positive correlation; The negative value is a negative correlation

[‡]Pearson correlation; [‡]Spearman correlation

Discussion

This study compared the TMJ and mandible dimensions and angles between skeletal Class III patients with skeletal symmetry and asymmetry using CBCT. The intra-examiner and inter-examiner reliabilities were good-excellent in all parameters, indicating that the measurements were reliable. To explain the cause of the skeletal asymmetry, genetic factors play an important role. The expression of genes, such as NFATC1, SOX5, NBAS, and TCF7L1, was found to be associated with facial asymmetry phenotypes.¹³ From an epidemiological perspective, patients with Skeletal Class III often exhibit greater skeletal asymmetry compared with those with Skeletal Class I or Class II.¹⁴ The incidence of Class III malocclusion was higher in an Asian population compared with a Caucasian population and an African population.^{15,16}

Focusing on the measurements, the comparison of the mediolateral condylar width across the different groups revealed that the mediolateral condylar width of the male non-deviated side was significantly higher compared with other groups, which coincides with a Taiwanese study.¹⁷ Moreover, the anteroposterior condylar width was similar to the mediolateral condylar width. These findings suggested that the non-deviated side of the condylar head of males with skeletal Class III was the largest. However, a Turkish study found that there

was no relationship between condylar shape and sex.¹⁸

The coronal condylar angle of the male deviated side was significantly lower compared with the female left side. However, a Chinese study found no significant difference in coronal condylar shape between sexes.¹⁹

In the present study, there was no significant difference between groups in the anterior space, posterior space, and superior joint space, which corresponded with study of Taiwanese skeletal Class III patients.¹⁷

A study of the joint spaces in Egyptian patients found that skeletal Class III had a significantly lower superior joint space compared with skeletal Class I and Class II.² The condylar axis in our study showed no significant difference, which agrees with a Korean study.⁷ However, the Taiwanese study found that the condylar axis of the non-deviated side was significantly higher compared with the symmetrical patients.¹⁷ The ramus width in females was significantly lower compared with the male deviated and non-deviated sides, which corresponded with an Indian study, which reported that the ramus width was larger in males compared with females.²⁰ It was found that the ramus height of the male non-deviated side was significantly higher compared with the female groups. The ramus height in a Korean study aligned with our findings that the ramus height on the non-deviated side of

skeletal Class III asymmetric patients was higher compared with the deviated side.²¹ This finding was similar to the Turkish study, which found that ramus height in males was higher than females.²² In this investigation, a decrease in mandibular height in females without asymmetry compared with males was observed. This finding aligned with a previous study conducted on adult Egyptians that found a significant difference between sexes, indicating that ramus height in males was higher compared with females.²³ In a Korean adult female skeletal Class III report, there was a significantly shorter ramus height on the deviated side compared with the non-deviated side.²⁴ The condylar height from a Korean study showed that the condylar height was higher on the non-deviated side compared with the deviated side. Moreover, the condylar height between the left and right sides of skeletal Class I was significantly different was reported.²¹ However, our study found no significant differences.

The results demonstrated that the correlation between the ramus height and lingula position in skeletal Class III symmetry patients was strong ($r = .743$), indicating a relationship between the lingula vertical position and the ramus height. The joint space analysis results were similar to a previous study that found there was no correlation between the anterior, superior, and posterior joint spaces in Chinese skeletal Class I.²⁵ The present study provides reference data for evaluating the temporomandibular area and characteristics of the mandible in skeletal Class III patients. The skeletal morphology in Class III symmetry and asymmetry patients can be used for orthodontics-orthognathic surgery treatment planning and evaluating surgical outcomes. The limitation of the TMJ study using CBCT was the articular disc in case that the CBCT could not evaluate the soft tissue precisely as the MRI could. The further study should be performed using MRI and CBCT to evaluate the bony structures and the articular disc.

Conclusions

Comparing the TMJ and mandible of Thai skeletal Class III patients with symmetry and asymmetry revealed

that the male non-deviated side exhibited the greatest mediolateral and anteroposterior condylar width, as well as the ramus height and the mandibular height. Thai skeletal Class III symmetry patients demonstrated a significant correlation between the lingula position and the ramus height, as well as between the mandibular height and the ramus height and between the mandibular height and the ramus width. This information can be useful to create the diagnostic criteria for TMJ and mandible dimensions among Thai skeletal Class III patients. The variability in TMJ and mandibular dimensions found in this study may be clinically important in orthodontic treatment planning and orthognathic surgery.

Acknowledgements

We are grateful to Dr. Kevin Tompkins for his critical review and language revision of this manuscript. Funding resources

Faculty of Dentistry, Chulalongkorn University
Disclosure

The authors have no conflicts of interest regarding this study.

References

1. Al-koshab M, Nambiar P, John J. Assessment of condyle and glenoid fossa morphology using CBCT in South-East Asians. *PLoS One* 2015;10(3):e0121682.
2. Alhammadi MS, Fayed MS, Labib A. Three-dimensional assessment of temporomandibular joints in skeletal Class I, Class II, and Class III malocclusions: Cone beam computed tomography analysis. *J World Fed Orthod* 2016;5(3):80-86.
3. Neto J EC, Bueno M, Guedes O, Porto O, Pécora J. Mandibular condyle dimensional changes in subjects from 3 to 20 years of age using Cone-Beam Computed Tomography A preliminary study. *Dental Press J Orthod* 2010;15(5):172-81.
4. Karlo CA, Stolzmann P, Habernig S, et al. Size, shape and age-related changes of the mandibular condyle during childhood. *Eur Radiol* 2010;20(10):2512-7.
5. Hadjidakis DJ, Androulakis, II. Bone remodeling. *Ann N Y Acad Sci* 2006;1092:385-96.
6. Gomes AF, Nejaim Y, Brasil DM, et al. Assessment of Volume and Height of the Coronoid Process in Patients With Different Facial Types and Skeletal Classes: A Cone-Beam Computed Tomography Study. *J Oral Maxillofac Surg* 2015;73(7):1395 e1-5.

7. Kim HO, Lee W, Kook YA, Kim Y. Comparison of the condyle-fossa relationship between skeletal class III malocclusion patients with and without asymmetry: a retrospective three-dimensional cone-beam computed tomography study. *Korean J Orthod* 2013;43(5):209-17.
8. Larsen MK. Indications for orthognathic surgery-a review. *OHDM* 2017;16(2):1-13.
9. Crespo Trujillo AZ, López AF. Skeletal class III with laterognathia and lower facial third asymmetry. Surgical-orthodontic treatment. *Revista Mexicana de Ortodoncia* 2017;5(2):e120-e26.
10. Dahlstrom L, Lindvall AM. Assessment of temporomandibular joint disease by panoramic radiography: reliability and validity in relation to tomography. *Dentomaxillofac Radiol* 1996;25(4):197-201.
11. Hintze H, Wiese M, Wenzel A. Cone beam CT and conventional tomography for the detection of morphological temporomandibular joint changes. *Dentomaxillofac Radiol* 2007;36(4):192-7.
12. Honda K, Arai Y, Kashima M, *et al.* Evaluation of the usefulness of the limited cone-beam CT (3DX) in the assessment of the thickness of the roof of the glenoid fossa of the temporomandibular joint. *Dentomaxillofac Radiol* 2004;33(6):391-95.
13. Rolfe S, Lee SI, Shapiro L. Associations Between Genetic Data and Quantitative Assessment of Normal Facial Asymmetry. *Front Genet* 2018;9:659.
14. Evangelista K, Teodoro AB, Bianchi J, *et al.* Prevalence of mandibular asymmetry in different skeletal sagittal patterns. *Angle Orthod* 2022;92(1):118-26.
15. Kapadia RM, Shah AP, Diyora SD, Rathva VJ. Non-surgical treatment of skeletal class III malocclusion. *BMJ Case Rep* 2014;2014.
16. Hardy DK, Cubas YP, Orellana MF. Prevalence of angle class III malocclusion: A systematic review and meta-analysis. *Open Journal of Epidemiology* 2012;02(04):75-82.
17. Chou ST, Wang JL, Chen SC, *et al.* Correlation between facial asymmetry of skeletal class III jaw relationship and morphology of the temporomandibular joint: A cone beam computed tomography study. *J Dent Sci* 2023;18(3):1031-41.
18. Tassoker M KA, Akin D, Sener S. evaluation of mandibular notch coronoid process and mandibular condyle configurations with cone beam computed tomography. *J Biomed Res* 2017;28(19):8327-35.
19. Mohsen AM, Ye J, Al-Nasri A, *et al.* Three-dimensional evaluation of the mandibular condyle in adults with various skeletal patterns. *Korean J Orthod* 2023;53(2):67-76.
20. Sairam V, Geetha Malika MV, Kumar PB, Naresh G, Raju GP. Determination of sexual dimorphism in humans by measurements of mandible on digital panoramic radiographs. *Contemp Clin Dent* 2016;7(4):434-39.
21. Lee H, Bayome M, Kim SH, *et al.* Mandibular dimensions of subjects with asymmetric skeletal class III malocclusion and normal occlusion compared with cone-beam computed tomography. *Am J Orthod Dentofacial Orthop* 2012;142(2):179-85.
22. Okkesim A, Sezen Erhamza T. Assessment of mandibular ramus for sex determination: Retrospective study. *J Oral Biol Craniofac Res* 2020;10(4):569-72.
23. Motawei SM, Helaly AMN, Aboelmaaty WM, *et al.* Length of the ramus of the mandible as an indicator of chronological age and sex: A study in a group of Egyptians. *Forensic Sci Int* 2020;2.
24. Baek S-H, Cho I-S, Chang Y-I, Kim M-J. Skeletodental factors affecting chin point deviation in female patients with class III malocclusion and facial asymmetry: a three-dimensional analysis using computed tomography. *Oral Surg Oral Med Oral Pathol Oral Radiol Endod* 2007;104(5):628-39.
25. Abdulqader AA, Ren L, Alhammadi M, Abdu ZA, Mohamed AAS. Three-dimensional analysis of temporomandibular joint in Chinese adults with normal occlusion and harmonious skeleton. *Oral Radiol* 2020;36(4):371-82.